

# Ultrasound screening for neoplasms in children up to 6 years old

Grzegorz Jedrzejewski, MD<sup>a,\*</sup>, Magdalena M. Wozniak, MD<sup>a</sup>, Agata Pawelec, MD<sup>a</sup>, Albert Matera, MD<sup>a</sup>, Magdalena Kunach, MD<sup>a</sup>, Tomasz Madej, MD<sup>a</sup>, Andrzej P. Wieczorek, MD<sup>a</sup>, Katarzyna Nowakowska, MD<sup>b</sup>

## Abstract

The aim of the ultrasound (US) screening program was to detect neoplastic lesions in children, together with other pathologies of the developmental age in the area of the neck, abdomen, female pelvis, and scrotum in boys.

US screening scans, including cervical, abdominal, pelvic, and scrotal US, were performed in the population of asymptomatic children aged from 9 months to 6 years. The children were scanned in Mobile Pediatric US Unit, consisting of 2 independent consulting rooms.

The scans of 14,324 children were analyzed, 7247 boys and 7077 girls. Totally 42,538 US examinations were performed, including 14,187 cervical scans, 14,259 abdominal scans, 6942 female pelvic scans, and 7150 scrotal scans. Totally 5426 abnormalities were detected, which represent 12.7% of all examinations and 30% of patients. Three tumors were recognized, which are renal malignant tumor diagnosed as Wilms tumor, neurogenic tumor of the rib, and teratoma of the testis.

US screening in pediatric population can be used to reveal lesions inaccessible to clinical examination, like tumors or other pathologies of developmental age before the onset of clinical symptoms. Due to the large number of detected abnormalities it should be recommended to the whole population of certain age.

**Abbreviation:** US = ultrasound.

**Keywords:** childhood cancer, no to neoplasms in children program, screening, ultrasound

## 1. Introduction

Screening imaging studies are generally applied in the diagnosis of cancer in adults. Rarely they relate to the pediatric population. Some attempts of screening in children, but not directed toward tumors, had been made in the diagnosis of subclinical varicocele,<sup>[1]</sup> brain lesions,<sup>[2]</sup> or adrenal hemorrhage in newborn infants.<sup>[3]</sup> There are no known attempts at performing screening imaging studies focused on neoplasms in wider pediatric population.

In Poland, the annual number of new cases of malignant tumors ranges from 102 to 118 per 1 million children and

adolescents below the age of 18.<sup>[4]</sup> Peak incidence during the earliest years of life features embryonic tumors like hepatoblastoma, nephroblastoma, or neuroblastoma. Out of these tumors the highest incidence rate is 9.3 for neuroblastoma, slightly lower for nephroblastoma –7.4 and lowest for hepatoblastoma –1.3.<sup>[5]</sup> Unfortunately in Poland these tumors are usually detected as large masses in rather advanced stage (III or IV),<sup>[4]</sup> so prevention and early detection of cancer at the developmental age should become a priority for national health policy. In case of pediatric population, noninvasiveness of the screening method was of great importance, therefore an attempt of ultrasound (US) screening test for the detection of neoplastic lesions in children in less advanced stages to improve prognosis and treatment of young patients was performed. Within the “No to neoplasms in children” program, Ronald McDonald Foundation since 2005 established National Ultrasound Screening Program for children on board of the special medical mobile ambulance. Every year almost 4000 children are scanned. An additional objective of the program was to detect other pathologies of the developmental age, such as congenital anomalies of the urinary tract, in the period before the onset of clinical symptoms.

## 2. Methods

Screening US scans, including cervical, abdominal, pelvic, and scrotal US, were performed in the population of asymptomatic children aged from 9 months to 6 years. The study protocol was proposed by a national consultant in the field of pediatric oncology in cooperation with pediatric radiologists. It was based on the incidence of childhood cancers in Poland for particular age groups.<sup>[4]</sup> The participation in the study was voluntary. Parents of children at particular age were invited to participate in the study by press announcements. There was huge interest in the

Editor: Alberto Stephano Tagliafico.

Funding/support: The Ultrasound Screening Program in children was organized by Ronald McDonald Foundation; The role of the Funding Source was the organization of research and covering all costs associated with these studies.

There was no role of the Funding Source in the preparation of the manuscript.

The authors have no conflicts of interest to disclose.

<sup>a</sup> Department of Pediatric Radiology, Medical University of Lublin, Lublin, <sup>b</sup> Ronald McDonald Foundation, Warsaw, Poland.

\* Correspondence: Grzegorz Jedrzejewski, Department of Pediatric Radiology, Medical University of Lublin, Gebali 6, 20-093 Lublin, Poland (e-mail: gjedrzejewski@wp.pl).

Copyright © 2016 the Author(s). Published by Wolters Kluwer Health, Inc. All rights reserved.

This is an open access article distributed under the terms of the Creative Commons Attribution-Non Commercial-No Derivatives License 4.0 (CCBY-NC-ND), where it is permissible to download and share the work provided it is properly cited. The work cannot be changed in any way or used commercially.

Medicine (2016) 95:42(e5124)

Received: 11 March 2016 / Received in final form: 28 August 2016 / Accepted: 22 September 2016

<http://dx.doi.org/10.1097/MD.0000000000005124>



Figure 1. The ambulance (upper image) with pediatric ultrasound (US) unit (bottom image).

program; however, only small part of the population could benefit from the studies. The children were scanned in Mobile Pediatric US Unit, containing of 2 independent consulting rooms (Fig. 1). Informed consent was received from all parents in this study. The ambulance traveled around the country, mainly to the urban centers. Two experienced pediatric radiologists performed examinations simultaneously, overall 12 pediatric radiologists took part in the project. All scans were performed according to standardized protocols.

Initially 2 SonoAce PICO US scanners with 2 probes: convex C 3-7 ED and linear L 5-9 EC, with power and color Doppler applications were used (Samsung Medison, Seoul, South Korea), recently replaced with similarly equipped Esaote Mylab scanners (Esaote, Florence, Italy).

In case of detection of any abnormality the children were referred for further diagnosis or control studies to family doctors. In most cases, the researchers were informed about the results of follow-up, especially about proven malignancies.

The Institutional Ethical Committee approved our protocol (KE-0254/39/2011).

### 3. Results

The scans of 14,324 children were analyzed in this study, 7247 boys and 7077 girls. Totally 42,538 US examinations were performed, including 14,187 cervical scans, 14,259 abdominal scans, 6942 female pelvic scans, and 7150 scrotal scans.

The results are divided into specific areas of interest, such as the neck, abdominal cavity, urinary tract, and the male and female reproductive system. The occurrence frequency of the main pathologies are included in Tables 1-4. Totally, 5426 abnormalities were detected which represent 12.7% of all examinations and 30% of patients – some children had more than one abnormality. In most cases, a US was sufficient to establish the final diagnosis. In 1538 cases (3.6%) there were suggested specialist consultations, and in 938 cases (2.2%) further imaging studies were advised.

Table 1

#### The abnormalities of the neck.

Abnormalities of the neck	N	% (from 14,187)
Enlarged lymph nodes	2309	16.12
Focal thyroid lesions	157	1.10
Thyroid cyst	8	0.06
Thyroid calcifications	2	0.01
Inhomogeneous thyroid echostructure	27	0.19
Enlarged thyroid gland	6	0.05
Hypoplasia of the thyroid gland	4	0.03
Asymmetry of the thyroid lobes	5	0.04
Agensis of the thyroid lobe	4	0.03
Hemangioma of the neck	5	0.04
Cervical medial cyst	18	0.13
Branchial cleft cyst	3	0.02

**Table 2**  
**The abdominal abnormalities.**

Abdominal abnormalities	N	% (from 14,259)
Hepatomegaly	35	0.24
Abnormal liver echostructure	5	0.04
Focal lesions of the liver	4	0.03
Calcification in the liver	2	0.01
Cyst of the liver	4	0.03
Hemangioma of the liver	2	0.01
Cholelithiasis	13	0.09
Polyp of the gallbladder	8	0.06
Splenomegaly	195	1.36
Accessory spleen	1358	9.48
Splenic cyst	13	0.09
Focal lesion of the spleen	2	0.01
Calcifications in the spleen	2	0.01
Abnormal echostructure of the spleen	1	0.01
Situs inversus	1	0.01
Enlarged abdominal lymph nodes	50	0.35
Cavernous transformation of the portal vein	1	0.01
Abnormal pancreas echostructure	6	0.04
Tumor of the rib	1	0.01

Highest number of abnormalities were detected in the neck US. They were found in 2575 children, which represent nearly 18% of all patients with examinations of the neck. Changes in abdominal US were found in 1384 cases (9.7%). Abnormalities of the urinary tract were diagnosed in 554 children (3.9%), of the male reproductive system in 1461 boys (20.4%) and female reproductive system in 55 girls (0.8%).

Until now, in 14,459 children, 3 malignant tumors were detected, which represent 0.02% of the examined population. These are renal malignant tumor diagnosed as Wilms tumor, neurogenic tumor of the rib (Fig. 2), and teratoma of the testis (Fig. 3). All tumors were confirmed by histological examinations.

**4. Discussion**

The intention of screening program is to identify disease in a community as early as possible, thus enabling earlier intervention

**Table 3**  
**The urinary tract abnormalities.**

Urinary tract abnormalities	N	% (from 14,259)
Agenesis of one kidney	23	0.16
Hypoplasia of the kidney	14	0.10
Dystopic kidney	12	0.08
Dystopia renis cruciata	1	0.01
Hoerschoe kidney	15	0.10
Duplication of the collecting systems	67	0.47
Renal focal lesion	5	0.03
Wilms tumor	1	0.01
Ranal cyst	18	0.13
Dilation of the collecting system	320	2.23
Extrarenal pelvis	8	0.06
Ureter dilation	24	0.17
Asymmetry in kidney length	14	0.10
Abnormal renal echostructure	5	0.03
Thickened bladder wall	14	0.10
Ureterocele	7	0.05
Renal stones	3	0.02
Nephrocalcinosis	1	0.01

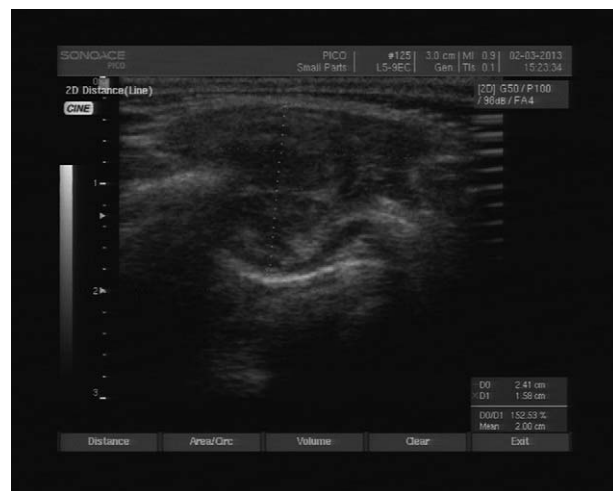**Table 4**  
**The reproductive system abnormalities.**

Male reproductive system abnormalities	N	% (from 7150)
Undescended testis	486	6.80
Mobile testis	592	8.28
Agenesis of the testis	26	0.36
Hypoplasia of the testis	10	0.14
Abnormal testis echostructure	3	0.04
Focal testis lesion	3	0.04
Teratoma of the testis	1	0.01
Microolithiasis	30	0.42
Inguinal hernia	34	0.48
Hydrocele testis	197	2.76
Hydrocele of the spermatic cord	37	0.52
Varicocele	1	0.01
Cyst of the epididymis	31	0.43
Calcifications in the epididymis	9	0.13

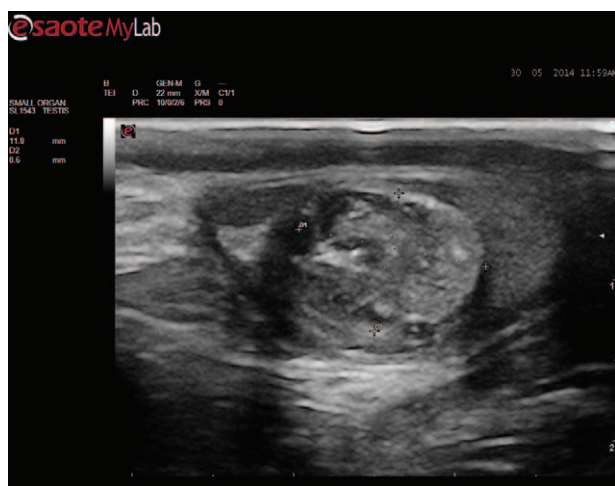
  

Female reproductive system abnormalities	N	% (from 7077)
Ovarian cyst (>10mm)	8	0.11
Enlarged follicles (3–10mm)	11	0.16
Enlarged inguinal lymph nodes	8	0.11
Free fluid in the Douglas cavity	24	0.34

and management in the hope of reducing mortality and suffering from a disease.<sup>[6]</sup> Screening exam should applicate the simple test, characterized by high sensitivity and specificity.<sup>[7]</sup> Nowadays it is difficult to imagine modern diagnostics without US. Due to its noninvasive nature, US examination is especially recommended for children, but until now it was not applied in extensive screening. The reason for this could be its low sensitivity and specificity, but in fact this has not been investigated. Some attempts of US screening had been made in the diagnosis of urinary tract abnormalities, brain or adrenal hemorrhage in newborn infants and in patients with cancer predisposition, for example, in children with Beckwith–Wiedemann syndrome.<sup>[1,2,8]</sup> In Poland, the pilot program of early detection of neoplasms, such as Wilms tumor and neuroblastoma, was introduced. Within it, screening US including cervical, abdominal, pelvical, and scrotal US were performed. Since the peak incidence of these neoplasms



**Figure 2.** Ultrasound (US) scan of the 2-year old girl. Neurogenic tumor of the rib (measurements).



**Figure 3.** Ultrasound (US) scan of the 3-year old boy. Teratoma of the testis (measurements).

occurs in early childhood, the population of children under 6 years of life were selected for exams.<sup>[4,5]</sup> It is quite a difficult age group in clinical practice, because most of the patients cannot precisely explain their complaints. Research has been directed to children that had not previously undergone an US examination and children without clinical symptoms. Overall 12 pediatric radiologists with at least 5 years experience in the field of pediatric US took part in the project.

To date almost 40,000 children were examined. The scans of about 15,000 children were analyzed, in whom 3 tumors were found, such as Wilms tumor, neurogenic tumor of the rib, and teratoma of the testis. Many other lesions were referred for further diagnosis, like thyroid, liver, spleen, pancreas, kidneys, and testes lesions, which in further observation were proved to be benign or developmental variations. At this point it should be mentioned the necessity of using additional diagnostic modalities. These were mainly supported by the family doctors, but many of patients could also benefit from additional examinations in the pediatric hospitals which cooperated with the program. The number of detected neoplasms, which would confirm the validity of such screening, is controversial. Such a state of things could be due to a random selection of partial populations from different regions, not covering the entire population of children in that age group in the areas covered by the survey. So, it was not fully reliable screening, that is why we should consider the possibility of introducing larger population of healthy children of a certain age for US. Anyway 1 case of Wilms tumor based on the number of examined patients gives incidence rate 7, which corresponds to the incidence rate of Wilms tumor of the whole population.<sup>[5]</sup> The sensitivity of US differs depending on the tumor type. In the case of these screening, the main idea was to detect the tumor and then direct the patient for further diagnosis.

Moreover, during the study, a large number of other abnormalities were found, with various degree of clinical significance, which were observed in approximately 30% of patients. They provide valuable information about the frequency of certain diseases, that may be conditions predisposing to the occurrence of neoplasms in the pediatric population. Starting from examinations of the neck, enlarged lymph nodes were found in 16% of children. Cervical lymphadenopathy was defined when cervical lymph nodes had more than 1 cm in long axis or 0.5 cm in short axis diameter. These dimensions do not apply to the

angular nodes that can reach a size of 2 to 3 cm in long axis and 1 cm in short axis. Although enlarged cervical lymph nodes are common in children, during the 1st 6 years of life, neuroblastoma and lymphoma are the most common tumors associated with cervical lymphadenopathy.<sup>[9]</sup> The role of US was to identify nodes suspected of malignancy, with the round shape and long axis to short axis ratio less than 2.<sup>[10]</sup> None of the enlarged lymph nodes in our study had such features and that is why all enlarged lymph nodes were diagnosed as benign lymphadenopathy. Abnormalities in the thyroid gland, which required further evaluation, were found in 1.5% of children. Incidental thyroid abnormalities detected in US examinations in children are commonly identified, but have not been well documented.<sup>[11]</sup> These might pose a clinical dilemma regarding management. Follow-up studies and laboratory investigations can lead to increased anxiety of families and additional expenses for the health care system.<sup>[11]</sup> Our data show no development of thyroid dysfunction or malignancy in this group of patients.

In abdominal US, an interesting observation related to the presence of additional spleen was noticed, which occurred in approximately 10% of children. Fortunately, this is not a clinically significant variety. Other common pathologies concerned enlargement of the liver and spleen and mesenteric lymph nodes.

Most clinically significant information was obtained during the study of the urogenital system. Approximately in 0.2% of the children agenesis of the one kidney was diagnosed and 0.1% of the children had a horseshoe kidney. The most common urinary tract pathology was related to dilation of collecting systems of the kidneys, reflecting changes in development and a potential risk for urinary tract infections or already present postinflammatory changes. Renal congenital defect may give no symptoms for a long time, but potential complications can be very serious. A significant number of abnormalities were related to scrotal pathologies in male. The study concerning those observation was published in 2012, in the *Early Human Development Journal*.<sup>[12]</sup> Many pathologies such as an undescended and migrating testis, microlithiasis are proven conditions predisposing to the occurrence of cancer, so treatment or follow-up of those is essentially the prevention of tumors. In case of the female reproductive system, no significant pathology in the course of research was found. Simple ovarian cysts with a diameter up to 10 mm should be considered as normal findings which require no intervention. Larger cysts should be monitored.<sup>[13]</sup>

In summary, if not for cancer screening, then for multidirectional screen tests of the abdomen and pelvis or scrotum such a scheme could be introduced. Authors realize that there is a potential risk of this program which may lead to unnecessary and even risky procedures, but over many years of research some experience have been gained in capturing most dangerous pathologies. The program is reaching the smaller centers, with difficult access to specialists and US exams. What is more awareness of not only the parents whose children attended to exams, but also the entire communities is raised.

## References

- [1] Cervellione RM, Corroppolo M, Bianchi A. Subclinical varicocele in the pediatric age group. *J Urol* 2008;179:717–9.
- [2] Wang LW, Huang CC, Yeh TF. Major brain lesions detected on sonographic screening of apparently normal term neonates. *Neuroradiology* 2004;46:368–73.
- [3] Gover A, Bader D, Weinger-Abend M, et al. Head ultrasonography as a screening tool in apparently healthy asymptomatic term neonates. *IMAJ* 2011;13:9–13.

- [4] Kowalczyk J, Dudkiewicz E, Balwierz W, et al. Incidence of childhood cancers in Poland in 1995–1999. *Med Sci Monit* 2002;8:587–90.
- [5] Lewandowska A. Cancer epidemiology and prevention in children and adolescents – view thesis. *Int J Pediatr Child Health* 2013;1:19–26.
- [6] Lynge E, Tornberg S, von Karsa L, et al. Determinants of successful implementation of population-based cancer screening programmes. *Eur J Cancer* 2012;48:743–8.
- [7] Hakama M, Coleman M, Alexe D-M, et al. Cancer screening: evidence and practice in Europe 2008. *Eur J Cancer* 2008;44:1404–13.
- [8] McNeil E, Brown E, Ching A, et al. Screening for Wilms tumor and hepatoblastoma in children with Beckwith-Wiedemann syndromes: a cost effective models. *Med Pediatr Oncol* 2001;37:349–56.
- [9] Pandey A, Kureel SN, Pandey J, et al. Chronic cervical lymphadenopathy in children. *Role Ultrasonogr* 2012;17:58–62.
- [10] Batko T, Kosiak W. Value of ultrasound of lymph nodes in children and adolescents in the family doctor's office and in pediatric practice – own investigations. *Dev Period Med* 2013;17:137–42.
- [11] Avula S, Daneman A, Navarro OM, et al. Incidental thyroid abnormalities identified on neck US for non-thyroid disorders. *Pediatr Radiol* 2010;40:1774–80.
- [12] Jedrzejewski G, Wozniak MM, Madej T, et al. The differences in testicular volumes in boys 8-36 months old with undescended, retractile and hydrocele testis – usefulness of scrotal screening ultrasound. *Early Hum Dev* 2012;88:185–9.
- [13] Templeman C. Ovarian cysts. *J Pediatr Adolesc Gynecol* 2004;17:297–8.